

IMPACT OF QUERCETIN SUPPLEMENTATION ON TESTICULAR FUNCTIONS IN SUMMER HEAT-STRESSED RABBITS

NASEER Z. , AHMAD E.  †, AKSOY M.  ‡, EPIKMEN E.T. 

*Faculty of Veterinary and Animal Sciences, Pir Mehr Ali Shah Arid Agriculture University, RAWALPINDI 46000, Pakistan.

†Department of Clinical Sciences, Faculty of Veterinary Sciences, Bahauddin Zakariya University, MULTAN 66000, Pakistan.

‡Dept. of Reproduction and Artificial Insemination, Faculty of Veterinary Medicine, Adnan Menderes University, AYDIN 09020, Turkey.

†Department of Pathology, Faculty of Veterinary Medicine, Adnan Menderes University, AYDIN 09020, Turkey.

Abstract: The current study was designed to determine the effects of dietary quercetin on epididymal sperm and testicular changes in male rabbits during summer heat stress (HS). Twelve adult male New Zealand white rabbits were submitted to summer heat conditions (temperature-humidity index 29.9 ± 1.2). One group was fed a basal ration (BR; $n=6$), whereas the other group was fed the same basal diet supplemented with quercetin (30 mg/kg d; Que-BR; $n=6$) for 60 d, and both groups were sacrificed at the end of the experiment. Epididymis and testicles isolation was done for sperm, histopathology and apoptosis assessments. The results showed that quercetin improved epididymis weight, but did not affect other testicular dimensions except testicular length. A significant improvement was observed in epididymal sperm motility, concentration, kinematic parameters, viability, mitochondrial potential and acrosome integrity in Que-BR compared to the BR group. Lowered serum malondialdehyde level was observed in quercetin supplemented rabbits. Moreover, the quercetin supplementation maintained the interstitial stroma, seminiferous tubules architecture, germinal and Sertoli cells under HS, decreasing the apoptotic germ cell rate in seminiferous tubules. In conclusion, HS condition affects the sperm and testes configurations in rabbits and dietary quercetin minimises oxidative stress, which in turn protects the testes and sperm against HS induced damage.

Key Words: quercetin, heat stress, testes, sperm, apoptosis, rabbit.

INTRODUCTION

In mammals, the process of spermatogenesis in a regular manner in the testes is maintained below body temperature. High testicular temperature affects the spermatogenesis process, which further lowers the sperm quality. All stages of testicular germ cells are equally susceptible to heat stress (HS), which affects the histology of each testicular compartment. It has been observed that sperm exposed to HS had a low fertilising capacity and resultant embryos growth is uncertain due to induced degeneration activity of sperm (Yaeram *et al.*, 2006). In addition, oxidative stress induced by HS also provides a ground for lowered male reproductive efficiency (Turner and Lysiak, 2008). The oxidative stress elicits the apoptosis process in the germ cells due to imbalance in the production of antioxidant enzymes and reactive oxygen species (ROS). The altered testes histology and rearrangement in the membranous structure are the major HS associated consequences of oxidative stress (Aldemir *et al.*, 2014; Bharti *et al.*, 2014). In this scenario, to combat the oxidative stress under HS, it is speculated that the dietary provision of natural antioxidant amalgams can be used as an ameliorative and therapeutic strategy to prevent the HS related injuries during spermatogenesis (El-Hanoun *et al.*, 2014).

Quercetin, a polyphenolic compound, is found in different fruits and works as pro- and antioxidant. Its pro- or antioxidant property relies on the availability of quercetin concentration. In earlier studies, it was noted that quercetin

Correspondence: Z. Nasser, zahidnaseer@uaar.edu.pk. Received October 2019 - Accepted February 2020.

<https://doi.org/10.4995/wrs.2020.12420>

attenuates oxidative stress in male germ cells induced by different compounds such as cadmium (Farombi *et al.*, 2012; Badr *et al.*, 2019), atrazine (Abarikwu *et al.*, 2012), diethylstilboestrol (Bharti *et al.*, 2014; Li *et al.*, 2010), tetrachlorodibenzodioxin (Ciftci *et al.*, 2012), carbon tetrachloride (Sonmez *et al.*, 2014), streptozotocin (Khaki *et al.*, 2010) and cisplatin (Aldemir *et al.*, 2014). Uptake of quercetin in daily food enhances the plasma antioxidant levels; in turn, it maintains the sperm integrity in testes by reducing the release of ROS (Hu *et al.*, 2015). However, its role in testicular functions has not been studied yet. In this scenario, the current experiment was conducted to explore the ability of quercetin to protect testes and epididymal sperm against HS induced changes.

MATERIALS AND METHODS

Prior to execution of the trial, approval was obtained from Animal Ethics Committee of University (ADÜ-HADYEK No. 64583101/2014/153) for the use of animals. The experiment was conducted during July-September 2016 at the Department of Reproduction and Artificial Insemination, Faculty of Veterinary Medicine, Adnan Menderes University, Işıkli, Aydın Turkey.

Temperature-humidity index

The ambient temperature and relative humidity were noted on a daily basis. The temperature-humidity index (THI) was calculated to observe the intensity of HS in rabbits (Marai *et al.*, 2001).

Animals and diets

Twelve sexually mature male White New Zealand rabbits with an average body weight of 2.9 ± 0.1 kg were included. The rabbit bucks were kept separately in galvanised enclosures. The rabbits were provided normal daylight (16-17 h) and were allowed a one-week period for acclimatisation. Later, the control group rabbits (BR; n=6) were given the basal ration (Table 1) and the treatment group (Que-BR; n=6) received quercetin (Quercetin hydrate, Sigma-Aldrich, St. Louis, USA) along with basal diet on a daily basis for 60 d. The treatment group rabbits were fed on standard pellet feed with quercetin supplementation (30 mg/kg d) by mixing in mesh feed (2 g quercetin/kg of feed) prior to pelleting. Feed intake by each rabbit was 120-140 g per day and fresh clean water was available round the clock.

Table 1: Ingredients and proximate analysis of nutrients in basal ration.

Feed Ingredients	g per 100 g
Corn	31
Wheat bran	25
Dried distillers grains soluble	15
Sunflower meal (36% protein)	9.5
Soybean	7
Safflower	5
Sunflower meal (28% protein)	3.5
Limestone	2.5
Salt	1
Vitamin-minerals mixture	0.5
Chemical Composition (g/100 g DM)	
Dry matter (DM) ¹	87.8
Crude protein ¹	17.4
Crude Fat ¹	4.8
Calculated metabolisable energy (MJ/kg)	10.73
Neutral detergent fiber ²	25.65
Acid detergent fiber ²	11.4
Ash ¹	4

¹Analyzed according to AOAC (2000) method for dry matter (method 934.01), crude protein (method 954.01), crude fat (method 920.39), and ash (method 942.05).

²Analyzed using the method described by Van Soest *et al.* (1991).

Sample collection

The rabbits were slaughtered at the end of the trial by cutting the jugular veins and carotid arteries. After ensuring complete exsanguination, cervical dislocation followed. Afterwards, the testes were isolated, dissecting the extra fat and tissues, and then weighed. The testes were for histological and apoptosis examination whereas the epididymides were used for sperm evaluation. In addition, blood samples were taken; after centrifugation, the harvested blood serum samples were stored at -20°C until analysis of malondialdehyde (MDA) concentration.

Histological examination

Initially, the testes were fixed in Bouin's solution for a period of 48 h. Afterwards, the fixed samples were processed for dehydration in alcohol and embedded in paraffin. A section of $5\ \mu\text{m}$ was prepared and deparaffinised. Later, the sections were stained with haematoxylin and eosin stains. After staining, the testicular tissue sections were observed in random fashion under blindfold conditions using standard light microscopy (Olympus BX 51, Japan). During the histopathological examination, the testes tissue sections were observed for any abnormality in the seminiferous tubules, germinal and Sertoli cells configuration. Differentiation between normal and degenerated/necrotic germ cells, tubular atrophy, exfoliated germ cells presence in the lumen of seminiferous tubules and interstitial vacuoles were particularly observed.

Evaluation of apoptosis of germ cells

A commercially available terminal deoxynucleotidyl transferase-mediated dUTP nick-end labeling (TUNEL) kit (Millipore, APOPTAG[®] Plus Peroxidase *in situ* Apoptosis Detection Kit) was used to observe the DNA damage in apoptotic cells. Briefly, the paraffinisation and deparaffinisation of tissue sections were through serial alcohol washings. Then, washing the sections in phosphate buffered saline (PBS) and incubation in proteinase K (20 mg/mL) was done for 15 min at room temperature. A second washing was performed for 2 min in distilled water. Afterwards, the sections were placed in 3% H_2O_2 solution for 5 min. Twofold washings were conducted for 5 min in PBS. Later, incubation of processed sections was done under humid air at 37°C for 1 h in the presence of a 50 μL drop of Terminal deoxynucleotidyl transferase (TdT) and fluorescein-dUTP (29- to 59-deoxyuridine triphosphate) for TUNEL reaction. The TUNEL reaction was examined using fluorescence microscopy. Afterwards, the sections were shaken for 15 s in 1/34 percent distilled water kit solution (Stop/Wash). Second incubation was done in similar order and PBS (3×1 min) was used for washing. Later, the slides sections were covered using previously prepared anti-digoxigenin peroxidase conjugate and incubation was done at room temperature for 30 min. PBS (4×2 min) was used again for washing. At the end, the slide sections were placed in 0.045% (v/v) containing 0.08% H_2O_2 (w/v) 3, 3-diaminobenzidine tetrahydrochloride (DAB) solution for 3-6 min for induction of chromogenic reaction. Finally, the reaction was noted using a bright phase microscope and washing of sections was performed using distilled water (3×1 min). Mayer's haematoxylin staining and dehydration using serial alcohol dilutions were done. The slide sections were then covered with a coverslip prior to observation. A similar order was followed for the preparation of negative control sections, except treatment for terminal transferase TUNEL reaction. The section slides were examined in a blindfold order by choosing five different fields (10 tubules/field) for recording of TUNEL-positive cells through bright phase microscopy ($\times 20$). TUNEL-positive staining indicates the degree of DNA damage by the illumination of brown coloration.

Evaluation of sperm characteristics

Adherent connective tissues to epididymis were removed and each epididymis was weighed. Next, the right cauda epididymis was used for sperm count and left cauda epididymis was used for other sperm variables. The epididymal sperm concentration was measured by haemocytometer. The epididymis was minced using fine scissors by placing in 1 mL of isotonic saline for 4 h. A volume of 10 μL of diluted sperm sample was taken for sperm count using counting chambers. Prior to observation, sperm were allowed to settle for 5 min.

The left cauda epididymis was immersed in TCG solution (Tris 276.5 mM, Citric acid 90.9 mM and Glucose 76.8 mM), minced finely and epididymal remnants were removed from the solution. The retrieved sperm were

used for motility, viability mitochondrial potential and acrosome reaction, adopting the procedure mentioned in previous studies (Naseer *et al.*, 2018).

Serum MDA estimation

The stored blood serum samples at -20°C were processed for MDA concentration. MDA level was observed using Thiobarbituric Acid (TBA) assay (Yagi, 1984). The MDA-TBA colour reaction was used as an indicator of lipid peroxidation degree in any biological matter. The MDA-TBA complex was observed through a spectrophotometer (Shimadzu UV-1601, Kyoto, Japan) at 532 nm and MDA values were presented as nmol/mL.

Statistical analysis

The data analyses were done using statistical software (SPSS; version 17.0.1 Chicago, IL, USA). Testicle dimensions, microscopic sperm variables, apoptotic cells and MDA concentration between HS and HS-Que groups were compared by Student *t*-test. A significance level of $P < 0.05$ was considered.

RESULTS

During the experimental trial, the ambient temperature and humidity remained unchanged. The average temperature was $33.5 \pm 1.7^{\circ}\text{C}$, with a $39.5 \pm 5.7\%$ relative humidity level. The THI was recorded at about 29.9 ± 1.2 , which indicates severe HS conditions for rabbits.

Unchanged ($P > 0.05$) testicular dimensions were observed across BR and Que-BR groups, except for the testicular length. Greater ($P < 0.05$) epididymal weight was recorded in quercetin supplemented rabbits compared to control (Table 2). Lowered ($P < 0.05$) sperm concentrations were observed in the BR group than in the Que-BR group. The sperm motility (progressive and total) and sperm kinetics variables [curvilinear velocity (VCL), straight linear velocity (VSL), average path velocity (VAP), sperm track straightness (STR), wobble (WOB) and amplitude of lateral head displacement (ALH)] were higher ($P < 0.05$) in Que-BR than BR group (Table 3). Similarly, improved ($P < 0.05$) sperm viability, sperm mitochondrial potential and sperm acrosome integrity were observed in the Que-BR group (Table 3).

The histological picture of testes showed that interstitial matter (Leydig cells, vasculature and supporting stroma), seminiferous tubules structures, germinal and Sertoli cells were normal across the groups. However, degenerated/necrotic germ cells, tubular atrophy, and exfoliated germ cells in seminiferous tubules lumen and interstitial vacuoles incidence were greater ($P < 0.05$) in heat exposed rabbits (Figure 1). Similarly, a higher rate ($P < 0.05$) of germ cell apoptosis in seminiferous tubules was seen in the BR group than in the Que-BR group (Table 2). In both groups, the germ cells underwent the apoptotic activity. However, all the germ cell stages of BR animals had apoptotic activity, whereas in the Que-BR group apoptotic activity was seen only in the spermatogonia stage (Figure 2). Lowered ($P < 0.05$) serum MDA concentration was measured in Que-BR rabbits compared to BR group (Figure 3).

Table 2: Effect of dietary quercetin provision on testicular dimensions and germ cell apoptotic rate (mean \pm standard error) in New Zealand White rabbits (approx. age 11 mo having 3 kg body weight) under heat stress (approx. temperature 33.5°C with 51% humidity level).

Parameters	Que-HS (n = 06)	HS (n = 06)	P-value
Testicular weight (g)	3.2 \pm 0.1	2.8 \pm 0.2	0.272
Testicular length (cm)	2.8 \pm 0.1	2.5 \pm 0.1	0.028
Testicular width (cm)	1.4 \pm 0.1	1.30 \pm 0.02	0.243
Epididymis weight (mg)	290.0 \pm 0.4	120.0 \pm 0.1	0.008
Apoptotic cells per seminiferous tubule (n)	20.4 \pm 7.6	55.8 \pm 20.7	0.007

The $P < 0.05$ shows the significance between the observed parameters.

Que-BR: quercetin supplemented basal ration; BR: non-supplemented basal ration.

Table 3: Effect of dietary quercetin supplementation on various sperm variables (mean±standard error) in New Zealand White rabbits (approx. age 11 mo having 3 kg body weight) under heat stress (approx. temperature 33.5°C with 51% humidity level).

Variables	Que-BR (n=06)	BR (n=06)	P-value
Sperm concentration (10 ⁶ /mL)	70.0±18.4	45.2±6.9	0.023
Progressive motility (%)	56.7±6.4	19.0±9.8	0.012
Total motility (%)	76.7±4.3	43.9±10.6	0.022
VCL (µm/s)	99.7±11.1	40.8±10.4	0.005
VSL (µm/s)	26.2±2.5	7.9±3.2	0.002
VAP (µm/s)	42.8±4.6	16.2±5.3	0.006
LIN (%)	26.7±1.9	17.8±3.6	0.061
STR (%)	61.5±2.2	46.7±5.6	0.041
WOB (%)	43.4±2.4	37.3±3.9	0.224
ALH(µm)	2.6±0.2	1.0±0.4	0.012
BCF (%)	15.1±1.4	3.5±2.4	0.004
Sperm mitochondrial potential (%)	70.2±3.4	49.1±5.1	0.009
Sperm viability (%)	68.7±3.1	56.3±2.9	0.022
Acrosome reacted sperm (%)	5.9±1.4	14.4±0.7	0.001

The values $P < 0.05$ shows the significance between the observed parameters.

Que-BR: quercetin supplemented basal ration; BR: non-supplemented basal ration. VCL = Curvilinear velocity; VSL = Straight linear velocity; VAP = Average path velocity; LIN = Linearity; STR = sperm track straightness; WOB = Wobble; ALH = Amplitude of lateral head displacement; BCF = Beat cross-frequency.

DISCUSSION

This experiment was the sequel to a previous study conducted by Naseer *et al.* (2018) on a rabbit semen response after quercetin supplementation, which reported that provision of quercetin would potentially improve the semen quality under summer HS. In the present study, dietary quercetin provision sustained the testicular morphology in rabbit exposed to HS. In addition, it also remarkably maintained the epididymal sperm reservoir and minimised the apoptotic rate in germ cells by lowering the oxidative stress. These findings are important to combat the collective

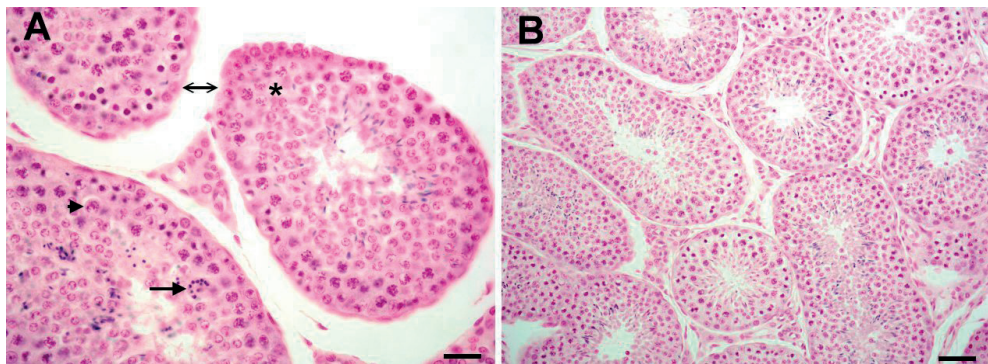


Figure 1: Microscopic view of [A: BR group, 20×] and [B: Que-BR group, 40×] testes of heat stress exposed rabbits. Panel (A) indicate sparse arrangement (double arrow) between the seminiferous tubules, vacuoles (asterisk), crescent-shaped primary spermatocytes (thick arrow) and apoptotic multinucleated giant cell (thin arrow). Panel (B) shows the relatively normal texture of seminiferous tubules. (Scale bar = 50 µm). Que-BR: quercetin supplemented basal ration; BR: non-supplemented basal ration.

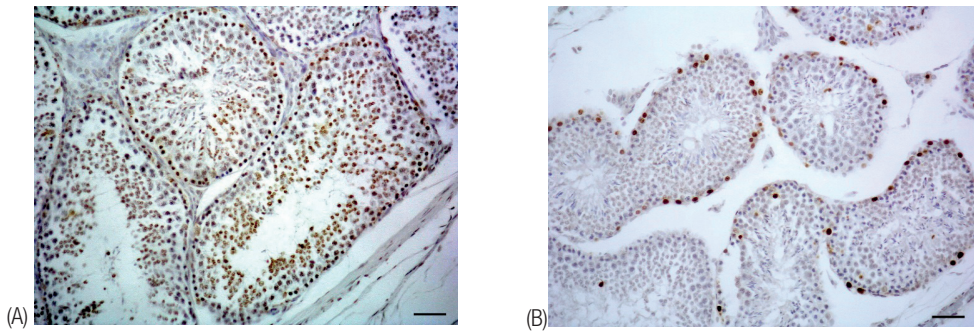


Figure 2: Microscopic view of [A: Que-BR group, 20×] and [B: BR group, 40×] testes after TUNEL staining of heat stress exposed rabbits. Only spermatogonia apoptotic germ cells are present in Que supplemented group (A), whereas, whole population of germ cells (spermatogonia, spermatocytes and spermatids) showing higher apoptosis rate in HS group (B). (Scale bar = 50 μm). Que-BR: quercetin supplemented basal ration; BR: non-supplemented basal ration.

influence of HS on sperm integrity and testicular architecture and to obtain the beneficial results of dietary quercetin in minimising the augmented effect of HS on the sperm or testes.

Strategies to minimise oxidative stress using quercetin have been tested and reported in both *in vitro* and *in vivo* experiments, with diverse findings. Some reports indicated an improvement in semen quality (Aldemir *et al.*, 2014; Al-Omair *et al.*, 2017) and testicular histograms (Bharti *et al.*, 2016; Abd-Ellah *et al.*, 2016); in contrast, others have found either no improvement on the variables cited above or a damaging effect of quercetin supplementation, such as increased rates of sperm morphology and reduced motility (Liang *et al.*, 2016; Filho *et al.*, 2017). Generally, the recommendation of oral antioxidants during infertility cases is a routine practice amongst human and veterinarian clinicians and this practice is based on the premise that increased seminal oxidative stress could be linked to the deficiency in seminal antioxidants (Fanaei *et al.*, 2014). Hence, the use of quercetin as an oral antioxidant could be an economical and safe choice to treat the infertility issues related to oxidative stress.

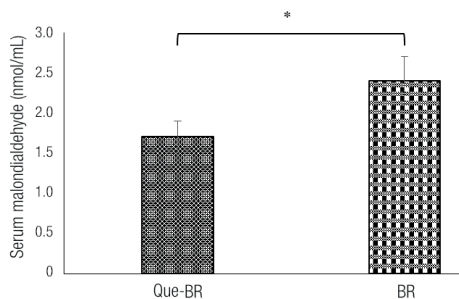


Figure 3: Effect of dietary quercetin supplementation on serum malondialdehyde concentration in heat stressed rabbits. *indicate significant difference between treatment groups. Que-BR=quercetin supplemented basal ration (n=06); BR=non-supplemented basal ration (n=06).

From our present findings, it seems that HS could have negatively affected sperm motility in rabbits. The sperm motility and sperm adenosine triphosphate (ATP) contents present in mitochondria are directly linked to each other and ATP contents are utilised by axonemal dynein for steady sperm movement (Odet *et al.*, 2013). Sperm motility can be restored by increasing the level of ATP in sperm suspending media (Gong *et al.*, 2017). Increased environmental (Gong *et al.*, 2017) or body temperature (Wechalekar *et al.*, 2010) affect the mitochondrial activity by inducing oxidative stress (Zhao *et al.*, 2006). Recently, it has been observed that oxidative phosphorylation level, ATP contents and sperm motility events are linked to each other (Guo *et al.*, 2017) and low mitochondrial activity due to HS affect the whole pathway of sperm motility (Gong *et al.*, 2017).

The occurrence of germ cell apoptosis is an essential indication that maintains the spermatogenesis process under physiological or pathological conditions (Vaux and

Flavell, 2000). The ratio of germ cells and Sertoli cells stabilisation and cellular homeostasis in the testis are regulated by this process (Baccetti *et al.*, 1996). There are numerous stress factors or chemical compounds that induce apoptosis of the germ cell in testes (Yin *et al.*, 1997; Bharti *et al.*, 2014; Sonmez *et al.*, 2014; Uygur *et al.*, 2014). The present findings indicate that a high proportion of germ cells in testis undergo apoptosis when the subject is exposed to HS. The testicular germ cells also underwent apoptosis in quercetin supplemented rabbit. Nevertheless, the apoptosis incidence and involved stages of spermatogenesis were remarkably higher in the non-supplemented group. This denotes that HS markedly increase the oxidative stress, which in turn increases the apoptosis rate in non-supplemented animals. Parrish *et al.* (2017) have reported similar observations in boar. The oxidative stress-apoptosis phenomenon has been explained in different HS related events (Kanter *et al.*, 2011). Previously, it has been observed that the spermatogonia stage is most vulnerable to apoptosis under HS owing to excessive ROS production (Maneesh *et al.*, 2005), whereas in the present study the quercetin intervention curtailed the ROS overproduction under HS that reduces the incidence of apoptosis in germ cells. Current findings concur with the earlier reports where quercetin provision decreased the apoptotic activity in germ cells against different toxins (Bharti *et al.*, 2014; Sonmez *et al.*, 2014; Uygur *et al.*, 2014; Hu *et al.*, 2015). It is speculated that quercetin may be involved in downregulation of the expression of apoptosis related proteins (BCL-2, BAX and FAS) and low activity of nitric oxide synthase, which in turn maintains the cell survival under HS.

During the histopathological examination of testes of the non-supplemented group, it was observed that HS induced irregularities in seminiferous tubules basement membrane, with affected spermatogenesis process. However, histopathological alterations did not occur greatly in the quercetin supplemented group. An improvement in testicular architecture of Que-BR rabbits under HS might be due to antioxidant property of quercetin. The current findings were supported by earlier reports where protective effects of quercetin against histological damage induced by different toxic agents were observed (Sonmez *et al.*, 2014; Altintas *et al.*, 2015; Khorsandi *et al.*, 2017; Osawe and Farombi, 2018; Badr *et al.*, 2019).

High MDA level under HS conditions is a well-known phenomenon in animals. Generally, the ROS react with the unsaturated fatty acids of the cell membranes and cause lipid peroxidation that leads to oxidative stress. In the current work, we recorded the decreased level of serum MDA in Que-BR under HS because of the antioxidant property of quercetin. We could not record the testicular MDA level, although the observation of MDA in testicular tissue is a benchmark to study the impact of any substance related to oxidative stress. Current data show that quercetin has a greater capacity to diffuse in membranes (Moridani *et al.*, 2003), which in turn scavenges the oxyradicals from the lipid bilayer of the cell. The pentahydroxyflavone structure of quercetin also works as a chelating substance of metal ions through the ortho-dihydroxy phenolic structure and scavenges the lipid alkoxyl and peroxy radicals.

In conclusion, quercetin intake protects the testicular architecture and sperm by minimising the oxidative stress provoked by summer heat conditions.

Acknowledgements: The authors are thankful to Ugur Ucan and Emrah Ipek for sampling.

Disclosure statement: None of the authors declares competing interests.

Funding: The financial support for this work was granted by ADU-BAP, Project number VTF-15034, Adnan Menderes University, Aydin, Turkey.

Notes on contributors: Nasser and Aksoy contributed to the design of the study, Nasser, Ahmad and, Epikmen conducted the experiments, analysed the data and wrote the manuscript. All authors read and approved the article for submission.

REFERENCES

- Abarikwu S.O., Pant A.B., Farombi E.O. 2012. The protective effects of quercetin on the cytotoxicity of atrazine on rat Sertoli-germ cell co-culture. *Int. J. Androlog.*, 35: 590-600. <https://doi.org/10.1111/j.1365-2605.2011.01239.x>
- Abd-Allah M.F., Aly H.A., Mokhles H.A., Abdel-Aziz A.H. 2016. Quercetin attenuates di-(2-ethylhexyl) phthalate-induced testicular toxicity in adult rats. *Human Experiment. Toxicol.*, 35: 232-243. <https://doi.org/10.1177/0960327115580602>
- Aldemir M., Okulu E., Kosemehmetoglu K., Ener K., Topal F., Evirgen O., Gurleyik E., Avci A. 2014. Evaluation of the protective effect of quercetin against cisplatin-induced renal and testis tissue damage and sperm parameters in rats. *Andrologia*, 46: 1089-1097. <https://doi.org/10.1111/and.12197>

- Al-Omair M.A., Sedky A., Ali A., Elsway H. 2017. Ameliorative potentials of quercetin against lead-induced hematological and testicular alterations in albino rats. *Chinese J. Physiol.*, 60: 54-61. <https://doi.org/10.4077/CJP2017.BAF440>
- Altintas R., Ciftci O., Aydin M., Akpolat N., Oguz F., Beytur A. 2015. Quercetin prevents docetaxel-induced testicular damage in rats. *Andrologia*, 47: 248-256. <https://doi.org/10.1111/and.12253>
- AOAC. 2000. Official Methods of Analysis. 17th Ed. *The Association of Official Analytical Chemists, Gaithersburg, MD, USA.*
- Baccetti B., Collodel G., Piomboni P. 1996. Apoptosis in human ejaculated sperm cells (*Notulae seminologicae* 9). *J. Submicro. Cytol. Pathol.*, 28: 587-596.
- Badr G.M., Elsway H., Sedky A., Eid R., Ali A., Abdallah B.M., Alzahrani A.M., Abdel-Moneim A.M. 2019. Protective effects of quercetin supplementation against short-term toxicity of cadmium-induced hematological impairment, hypothyroidism, and testicular disturbances in albino rats. *Environ. Sci. Pollut. Res.*, 26: 8202-8211. <https://doi.org/10.1007/s11356-019-04276-1>
- Bharti S., Misro M.M., Rai U. 2014. Quercetin supplementation restores testicular function and augments germ cell survival in the estrogenized rats. *Mol. Cell. Endocrinol.*, 383: 10-20. <https://doi.org/10.1016/j.mce.2013.11.021>
- Ciftci O., Aydin M., Ozdemir I., Vardi N. 2012. Quercetin prevents 2,3,7,8-tetrachlorodibenzo-p-dioxin-induced testicular damage in rats. *Andrologia*, 44: 164-173. <https://doi.org/10.1111/j.1439-0272.2010.01126.x>
- El-Hanoun A.M., Elkomy A.E., Fares W.A., Shahien E.H. 2014. Impact of royal jelly to improve reproductive performance of male rabbits under hot summer conditions. *World Rabbit Sci.*, 22: 241-248. <https://doi.org/10.4995/wrs.2014.1677>
- Fanaei H., Khayat S., Halvaei I., Ramezani V., Azizi Y., Kasaean A., Mardaneh J., Parvizi M.R., Akrami M. 2014. Effects of ascorbic acid on sperm motility, viability, acrosome reaction and DNA integrity in teratozoospermic samples. *Iranian J. Reproduct. Med.*, 12: 103-110.
- Farombi E.O., Adedara I.A., Akinrinde S.A., Ojo O.O., Eboh A.S. 2012. Protective effects of kolaviron and quercetin on cadmium-induced testicular damage and endocrine pathology in rats. *Andrologia*, 44: 273-284. <https://doi.org/10.1111/j.1439-0272.2012.01279.x>
- Filho J.S., Corcini C.D., Santos F.C.C., Ancianti A.N., Gatti N.L.S., Anastacio E., Mielke R., Nogueira C.E.W., Curcio B.R., Jr Varela A.S. 2017. Quercetin in equine frozen semen. *Cryo Letters*, 38: 299-304.
- Gong Y., Guo H., Zhang Z., Zhou H., Zhao R., He B. 2017. Heat stress reduces sperm motility via activation of glycogen synthase kinase-3 α and inhibition of mitochondrial protein import. *Front. Physiol.*, 8: 718. <https://doi.org/10.3389/fphys.2017.00718>
- Guo H., Gong Y., He B., Zhao R. 2017. Relationships between mitochondrial DNA content, mitochondrial activity, and boar sperm motility. *Theriogenology*, 87: 276-283. <https://doi.org/10.1016/j.theriogenology.2016.09.005>
- Hu J., Yu Q., Zhao F., Ji J., Jiang Z., Chen X., Gao P., Ren Y., Shao S., Zhang L., Yan M. 2015. Protection of quercetin against triptolide-induced apoptosis by suppressing oxidative stress in rat Leydig cells. *Chem. Biol. Interact.*, 240: 38-46. <https://doi.org/10.1016/j.cbi.2015.08.004>
- Jahan S., Ain Q.U., Ullah H. 2016. Therapeutic effects of quercetin against bisphenol A induced testicular damage in male Sprague Dawley rats. *Sys. Biol. Reprod. Med.*, 62: 114-124. <https://doi.org/10.3109/19396368.2015.1115139>
- Kanter M., Aktas C., Erbogaa M. 2011. Heat stress decreases testicular germ cell proliferation and increases apoptosis in short term: an immunohistochemical and ultrastructural study. *Toxicol. Ind. Health*, 29: 99-113. <https://doi.org/10.1177/0748233711425082>
- Khaki A., Fathiazad F., Nouri M., Khaki A., Maleki N.A., Khamnei H.J., Ahmadi P. 2010. Beneficial effects of quercetin on sperm parameters in streptozotocin-induced diabetic male rats. *Phytother. Res.*, 24: 1285-1291. <https://doi.org/10.1002/ptr.3100>
- Khorsandi L., Orazizadeh M., Moradi-Gharibvand N., Hemadi M., Mansouri E. 2017. Beneficial effects of quercetin on titanium dioxide nanoparticles induced spermatogenesis defects in mice. *Environment. Sci. Pollut. Res.*, 24: 5595-5606. <https://doi.org/10.1007/s11356-016-8325-2>
- Li G., Ma A., Shi W., Zhong X.H. 2010. Quercetin protects hamster spermatogenic cells from oxidative damage induced by diethylstilbestrol. *Andrologia*, 42: 285-290. <https://doi.org/10.1111/j.1439-0272.2009.00990.x>
- Liang X., Xia Z., Yan J., Wang Y., Xue S., Zhang X. 2016. Quercetin inhibits human sperm functions by reducing sperm [Ca²⁺]_i and tyrosine phosphorylation. *Pakistan J. Pharmaceutic. Sci.*, 29: 2391-2396.
- Maneesh M., Jayalakshmi H., Dutta S., Chakrabarti A., Vasudevan D.M. 2005. Role of oxidative stress in ethanol induced germ cell apoptosis - An experimental study in rats. *Indian J. Clin. Biochem.*, 20: 62-67. <https://doi.org/10.1007/BF02867402>
- Marai I.F.M., Habeeb A.A.M., Gad A.E. 2002. Rabbits' productive, reproductive and physiological performance traits as affected by heat stress: A review. *Livest. Prod. Sci.*, 78: 71-90. [https://doi.org/10.1016/S0301-6226\(02\)00091-X](https://doi.org/10.1016/S0301-6226(02)00091-X)
- Moridani M.Y., Pourahmad J., Bui H., Siraki A., O'Brien P.J. 2003. Dietary flavonoid iron complexes as cytoprotective superoxide radical scavengers. *Free Radic. Biol. Med.*, 34: 243-253. [https://doi.org/10.1016/S0891-5849\(02\)01241-8](https://doi.org/10.1016/S0891-5849(02)01241-8)
- Naseer Z., Ahmad E., Şahiner H.S., Epikmen E.T., Fiaz M., Yousuf M.R., Khan S.A., Serin İ., Ceylan A., Aksoy M. 2018. Dietary quercetin maintains the semen quality in rabbits under summer heat stress. *Theriogenology*, 122: 88-93. <https://doi.org/10.1016/j.theriogenology.2018.09.009>
- Odet F., Gabel S., London R.E., Goldberg E., Eddy E.M. 2013. Glycolysis and mitochondrial respiration in mouse LDHC-null sperm. *Biol. Reprod.*, 88: 1-7. <https://doi.org/10.1095/biolreprod.113.108530>
- Osawe S.O., Farombi E.O. 2018. Quercetin and rutin ameliorates sulphasalazine-induced spermiotoxicity, alterations in reproductive hormones and steroidogenic enzyme imbalance in rats. *Andrologia*, 50: e12981. <https://doi.org/10.1111/and.12981>
- Parrish J.J., Willenburg K.L., Gibbs K.M., Yagoda K.B., Krautkramer M.M., Loether T.M., Melo F.C.S.A. 2017. Scrotal insulation and sperm production in the boar. *Molecul. Reprod. Develop.*, 84: 969-978. <https://doi.org/10.1002/mrd.22841>
- Sönmez M., Türk G., Ceribas S., Ciftci M., Yüce A., Güvenc M., Kaya S.O., Cay M., Aksakal M. 2014. Quercetin attenuates carbon tetrachloride-induced testicular damage in rats. *Andrologia*, 46: 848-858. <https://doi.org/10.1111/and.12159>
- Turner T.T., Lysiak J.J. 2008. Oxidative stress: a common factor in testicular dysfunction. *J. Androl.*, 29: 488-498. <https://doi.org/10.2164/jandrol.108.005132>
- Uygun R., Yagmurca M., Alkoc O.A., Genc A., Songur A., Uçok K., Ozen O.A. 2014. Effects of quercetin and fish n-3 fatty acids on testicular injury induced by ethanol in rats. *Andrologia*, 46: 356-369. <https://doi.org/10.1111/and.12085>

- Van Soest P.J., Robertson J.B., Lewis B.A. 1991. Methods for dietary fiber, neutral detergent fiber, and nonstarch polysaccharides in relation to animal nutrition. *J. Dairy Sci.*, 74: 3583-3597. [https://doi.org/10.3168/jds.S0022-0302\(91\)78551-2](https://doi.org/10.3168/jds.S0022-0302(91)78551-2)
- Vaux D.L., Flavell R.A. 2000. Apoptosis genes and autoimmunity. *Current Opin. Immunol.*, 12: 719-724. [https://doi.org/10.1016/S0952-7915\(00\)00168-0](https://doi.org/10.1016/S0952-7915(00)00168-0)
- Wechalekar H., Setchell B.P., Peirce E.J., Ricci M., Leigh C., Breed W.G. 2010. Whole-body heat exposure induces membrane changes in spermatozoa from the cauda epididymidis of laboratory mice. *Asian J. Androl.*, 12: 591-598. <https://doi.org/10.1038/aja.2010.41>
- Yaeram J., Setchell B.P., Maddocks S. 2006. Effect of heat stress on the fertility of male mice *in vivo* and *in vitro*. *Reprod. Fert. Develop.*, 18: 647-653. <https://doi.org/10.1071/RD05022>
- Yagi K. 1984. Assay for blood plasma or serum. *Method. Enzymol.*, 105: 321-328. [https://doi.org/10.1016/S0076-6879\(84\)05042-4](https://doi.org/10.1016/S0076-6879(84)05042-4)
- Yin Y., Hawkins K.L., DeWolf W. C., Morgentaler A. 1997. Heat stress causes testicular germ cell apoptosis in adult mice. *J. Androl.*, 18: 159-165.
- Zhao Q.L., Fujiwara Y., Kondo T. 2006. Mechanism of cell death induction by nitroxide and hyperthermia. *Free Radic. Biol. Med.*, 40: 1131-1143. <https://doi.org/10.1016/j.freeradbiomed.2005.10.064>
-